

## Forensic Dentistry in a Southern Brazilian City

L.D. Conceição <sup>a,\*</sup>, N.R. Prietto <sup>b</sup>, R.H.A. Silva <sup>c</sup>, R.G. Lund <sup>d</sup>

<sup>a</sup> DDS, MSc student, Expertise General Institute, Secretary's Office of Justice and Security from Rio Grande do Sul, Pelotas(RS), Brazil

<sup>b</sup> Graduate student, School of Dentistry, Federal University of Pelotas, Pelotas(RS), Brazil

<sup>c</sup> DDS, MSc, PhD, Forensic Dentistry Unit, School of Dentistry of Ribeirão Preto, University of São Paulo, Ribeirão Preto(SP), Brazil

<sup>d</sup> DDS, MSc, PhD, Postgraduate Program in Dentistry, School of Dentistry, Federal University of Pelotas, Pelotas(RS), Brazil

\*Endereço de e-mail para correspondência: [rafael.lund@gmail.com](mailto:rafael.lund@gmail.com). Tel.: +55 53 3222-6690.

Recebido em 29/01/2015; Revisado em 31/03/2015; Aceito em 01/04/2015

---

### Resumo

Desde 1932, a inclusão obrigatória da Odontologia Legal no currículo das faculdades de odontologia no Brasil contribuiu para a disseminação desta ciência entre os estudantes de odontologia. Infelizmente, esses profissionais, por vezes, não acham este assunto relevante e apenas se preocupam com o assunto quando enfrentam um problema na área judicial. Este trabalho tem como objetivo relatar as rotinas, procedimentos e funções de um Posto Médico Legal, em Pelotas, cidade do sul do Brasil, porque estas situações são geralmente desconhecidas pelos cirurgiões-dentistas e este contato e conhecimento são importantes para que eles tenham uma compreensão mais precisa do trabalho do perito odonto-legista. Diferentes métodos de identificação humana (exames de arcada dentária, rugosidades palatinas e extrações de dentes para o exame de DNA da polpa dentária) são de responsabilidade do dentista forense. Além disso, o juiz pode nomear o dentista que faz o trabalho na área cível, criminal, trabalhista e administrativo em processos legais. Concluiu-se que a estrutura do Posto Médico Legal de uma cidade do sul do Brasil, como Pelotas, apresenta plenas condições para a prática Odontologia Legal, permitindo um trabalho interdisciplinar na busca de soluções de crimes. Por isso, é essencial para estimular e chamar a atenção para o estudo desta área nos países em desenvolvimento como o Brasil, onde o número de especialistas está a aumentar.

*Palavras-Chave:* Medicina Legal; Odontologia Forense; Antropologia Forense.

---

### Abstract

Since 1932, the compulsory inclusion of Forensic Dentistry in the curriculum of dental schools in Brazil has helped to disseminate this science among dental students. Unfortunately, these professionals sometimes do not find this matter relevant and only concern themselves with the subject when they first face a problem in the judicial area. This paper aims to report the routines, proceedings, and functions of a Legal Medical Station in Pelotas, a southern Brazilian city, because these situation are usually unknown by the dentists and this contact and knowledge are important for them to have a more precise understanding of the forensic dentist's work. Different oral methods of human identification (dental arch exams, palatal rugae, and tooth extractions for the examination of the DNA of the dental pulp) are responsibility of the forensic dentist. In addition, the judge can nominate the dentist who does the work on civil, criminal, labor and administrative in legal proceedings. We concluded that the structure of the Legal Medical Station in a southern Brazilian city, as Pelotas, presents full conditions for the Forensic Dentistry practice, allowing an interdisciplinary work in the search of crimes solutions. Hence, it is essential to stimulate and call attention to the study of this area in developing countries like Brazil, where the number of specialists is increasing.

*Keywords:* Forensic Medicine; Forensic Dentistry; Forensic Anthropology.

---

## 1. INTRODUÇÃO

Since 1932, the compulsory inclusion of Forensic Dentistry in the curriculum of dental schools in Brazil has helped to disseminate this science among dental students. It is well known that odontologists need special

knowledge in the field of forensics. In many countries, Forensic Dentistry is an established part of the dental education at schools or universities. Unfortunately, these professionals sometimes do not find this matter relevant and only concern themselves with the subject when they first face a problem in the judicial area.

The forensic dentist at the Legal Medical Institutes and similar institutions can also work as an expert or technical assistant in cases of civil, criminal, labor areas and in an administrative headquarter.

Forensic Dentistry is a field that has been defined in several ways. One of its most elegant concepts is that it represents the link between the dental and legal professions [1].

The area of forensic dentistry is a wide working field. According to the Brazilian Federal Council of Dentistry through resolution number 63/2005 [2], the scope of this specialty is defined as “the analysis, expertise and evaluation of the events related to the competence area of the dentist, and can, if the circumstances require, extend to other areas, if this will depend on the search of the truth, in the strict interest of the justice and the administration”.

Moreover, the competence areas that the expert in Forensic Dentistry is responsible can include: a) human identification; b) expert analysis in Civil, Criminal, and Labor Court; c) expert analysis in administrative area; d) expert analysis in evaluation and planning in labor hazard; e) forensic odontology; f) elaboration of records, reports, opinions and also of records and certificates; g) traumatology in forensic dentistry; h) forensic ballistics; i) logistics expert analysis in live, dead, complete or fragmented people; j) expert analysis in correlated vestiges, including blood or liquids from or in the oral cavity l) image examination; m) deontology; n) forensic dentistry orientation to the professional practice; and o) image examination with legal dental purposes [2].

Regarding their contribution to human identification, the examinations of dental elements and the structures of the stomatognathic system can be auxiliary tools to identify the corpses from their human remains. This is done through applicable methodologies such as examination of the conditions of the dental arches, palatal rugae, DNA extraction from dental structure (pulp, dentin, and cement), and the analysis of bite marks [3].

The application of forensic techniques has been used worldwide. It is important to remember that, in cases of mass disasters, the traumatic forces of the accident are so intense that the fragmentation and conflagration result in the preservation of only the most resistant post-mortem tissues of the victims, which are those derived from the human dentition. These become the main source for identification of the corpses [4-5].

Thus, the contribution of Forensic Dentistry and Forensic Anthropology can be seen through the identification of body remains, such as the skull, by comparing dental records, photos, and clinical records [1, 3-4]. Moreover, Forensic Dentistry can be useful in the identification of victims in mass disasters. It can differentiate between each of the victims involved in situations like natural disasters (such as the tsunamis in

2004) [1, 5-6], bus accidents involving body carbonization [6-7], plane crashes [8], fires [1], train accidents [9], military accidents and wars [10].

In Brazil, there were two airplane mass disasters in less than 10 months involving national companies. The first happened on 29 September 2006 in Mato Grosso State, when a 737-800 New Generation Boeing struck a N600L Legacy jet, resulting in 154 victims [11]. The second accident was on 17 July 2007, at the Congonhas airport, São Paulo, when an airbus lost control while landing, resulting in 199 deaths [12].

In this context, the work of the forensic dentist in the processes of post-mortem human identification of those subjects, which cannot be identified visually, or by other traditional means [13] has an irrefutable value. So, the forensic dentists provide a specialized contribution in future cases of mass accidents and other types of collective disasters [2].

The lack of data on dental expert reports in Brazil justifies the topic of this paper. Considering this, this paper aims to report the routines, proceedings, and functions of a Legal Medical Station in Pelotas, a southern Brazilian city, because these Stations are usually unknown by the dentists. However, this contact and knowledge is important for them to have a more precise understanding of the forensic dentist's work.

## 2. OVERVIEW

Pelotas city is in the very south of Brazil, close to the Uruguay border, and has 328.275 inhabitants according to 2010 Brazilian Demographic Census [14]. The Legal Medical Station is a reference for 11 cities with 600,000 inhabitants [15].

### 2.1 Expert's Routine

Law, through the Penal Process Code [16] rules the routine and the proceedings of the expert's work. In this sense, the purpose of the expert is to produce the criminal proof, which is the material element of a crime. This provides the Judge the opportunity of discovering the truth and forming his beliefs about the event based on the proof.

According to Rothwell [17], identification of the deceased is an important standard of civilized society, and dental means are an accurate and reliable way to ensure a proper identification. Using a methodical approach through a preliminary evaluation, postmortem examination, antemortem investigation, and comparison, an experienced forensic dentist can gather all of the requisite information necessary to reach a conclusion regarding identity of the deceased.

The identification process can be carried out on live people, corpses, skeletons, animals, and objects [3, 17].

The expert is responsible for the technical examinations of his specialty or competence to clarify the facts that are the object of the police inquiry or judicial process [18].

The official experts are those who work on the cases are public employees, for example, forensic physicians, forensic dentists, criminal experts, etc. In Pelotas city, the experts work in the Expertise General Institute after being approved by a public selection test. However, at the time of this paper, there was no forensic dentist on the Pelotas professional staff to act as the expert. Non-official experts, also called 'ad hoc' experts, are those set by the judge either to fill in for the official experts or to replace them, when for any reason they are hindered or rendered incapable to work [18].

The forensic physician will not interfere in all cases. This professional will verify the cause of death in cases of violence (homicide, suicide, and accident) and in cases of doubtful death (sudden and mistrust) [18].

## 2.2. The Function of the Medical Legal Station in Pelotas City, Brazil

Forensic physicians and expert technicians form the Legal Medical Station staff from Pelotas. The physicians are responsible for the necropsy exams and bodily injury exams. Many times, they also hold the post of Station Chief. The technicians are responsible for performing the necropsies, looking after local hygienic, sterilizing the work materials, registering the corpses, helping the experts in their tasks, conducting official vehicles, and all other correlated functions [18].

Directly connected to the Legal Medical Department are the Criminalistic Department and the Identification Department (Figure 1). The first has the objective of studying vestiges from the crime scene, physical person and identifying the authors of the penal infringement [3]. The second has the objective of establishing the person's identity by doing a detailed and meticulous study of the drawings of the papillary dermis, formed in the tiptoes, on the palm of the hands, and soles of the feet.

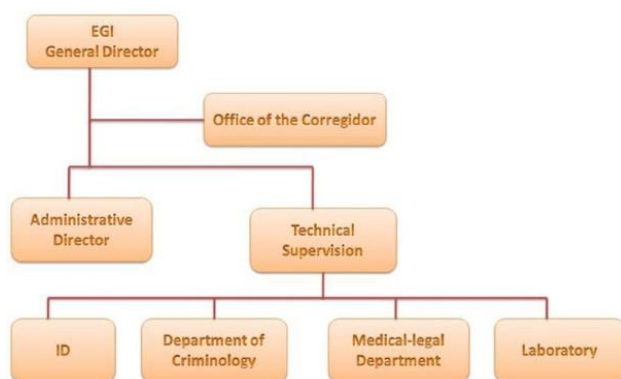


Figure 1. Organization of activities at the Legal Medicine Station.

Overall, the criminal investigation is a combination of proceedings and tasks capable of creating conditions to elucidate a crime and not just to worry about the subject's identification. It is important to remember that all segments in the Public Security have attributions and responsibilities in the process of criminal investigation. All tasks must be executed in harmony and cooperation, with the aim to guarantee the optimization of the final work: to solve the criminal investigation.

The expert's work in the Legal Medical Department from Pelotas starts with the commitment of a crime, which brings the police agencies (Military Brigade, Civil Police, Federal Highway Police, and/or Federal Police) into action.

Then, with the information about the crime, the police ascertain the need of an expert or not. Besides the police, on the procedural stage, the prosecutor or the judge can activate the expert's service. However, in most cases, the first person to be informed is the police chief because he is usually the one who has the responsibility for the inquiry [20]. The expert is compulsory, according to the Article 158 in the Brazilian Penal Process Code (1941) [16]:

When the infringement leaves vestiges, it is essential the direct or indirect body's offense exam, not being a substitute to the confession of the accused.

As long as the expert is required, the Criminal Department carries out the investigation in the crime scene and the Legal Medical Department removes the corpse, when necessary. After the corpse arrives in the morgue (Figure 2), it undergoes several routine proceedings, including weight and height measurement and a photograph to identify the victim. A form is filled with important information, such as date, time, type of death, corpse's data, decease declaration, further exam requisitions, etc. All these things guarantee that nothing is lost concerning the origin of the body and the proceedings performed on it.



Figure 2. Partial look of the necropsy's room at the Legal Medical Station, Pelotas-RS-Brazil.

After gathering all this information, the forensic physician is called to perform the necropsy exam. It is important to emphasize that, in Brazil; the necropsy can only be legally done six hours from time of death and before that only in cases of apparent death [16].

Usually, the necropsy analyses the body and all correlated things like clothing of the deceased. The external inspection identifies the gender, age, and physical characteristics. Since death, signs become visible 6 hours from time of death that is when all parts of the body are described in detail: head, neck, thorax, abdomen, upper and lower limbs, back, and external genitals. The internal examination of cavities: cranial, thoracic, and abdominal, except when the body condition finds unnecessary or when the evidence is enough to explain the cause of death [18].

The vertebral cavity must be examined in cases such as trauma by bullets from firearms, transit accidents, and others. The neck is inspected in cases of hanging, strangulation and choking.

When all the information is collected, a necropsy report will be typed telling what was found and the forensic physician answer questions and then sent to the responsible authority taking into consideration Article 160 of the Penal Process Code:

The expert report will be done in the maximum of 10 (ten) days, it could be postponed in exceptional cases, when required by the experts.

The report questions to be answered are usually: 1) Was there a death; 2) What was the reason of death; 3) What instrument caused the death; and 4) Was the death provoked by poisoning, fire, explosive, asphyxia, torture, or other cruel or insidious? After that, the physician signs the death certificate and then the body is released to the family.

### 2.3. Techniques of Human Identification

In the Legal Medical Department from Pelotas, several methods of corpse identification are used. First, the clothes are immediately and carefully examined, photographed, described in the necropsy's report, and stored. Within the clothes' pockets, it is possible to find an identity card, a driving license, and objects of personal use. These things will give information about the places the person has been or passed by, social status of the victim, etc. All this information is extremely valuable to reach initial conclusions about the corpse's identification (Figure 3).

However, evidence from clothing and personal belongings can lead to mistakes because loose objects can be mislaid or switched between bodies [20].

Second, after the necropsy exam the Identification Department searches for digital impressions of the person

in order to compare them with database files and identify the corpse by dactyloscopic method. This is also the time when the forensic dentist will be called for identify the corpse. The dentist has to fill a form with the corpse data, such as skin color, age, odontogram, and the description of the upper and lower dental arches.



**Figure 3.** Analysis of the victims' clothes and documents at the Legal Medical Station.

Rothwell [17] assumed that Forensic Dentistry methods play a key role in the identification of decomposed corpse remains. This is in accordance with Silva et al. [21] who do not restrict the forensic dentist field to the examination of dental vestiges, but extends it to several areas: anthropology, genetics, biochemistry, forensic ballistic, forensics thanatology and traumatology, radiology, prosopography, and the mixing of images.

To identify the corpse it is important to make a detailed study of the teeth and collect a great deal of information to compare against post-mortem and ante-mortem data, such as identification of decayed or filled teeth, individual position of the teeth and their respective anatomical characteristics, restorations and pathological components [3-4, 21]. There is emphasis on individual peculiarities, especially dental anomalies related to volume, number, shape, position, or eruption. Noted individual peculiarities formed from habits like bruxism, nail biting, esophagi, pipe smokers, and others. According to Legal Medical Department methods, the autopsy technicians uses instruments such as chisels, grinder and clamps to reach straight into the oral cavity and to help the forensic dentist make precise observations (Figures 4 and 5).

In cases of finding bones and/or the skull, the identification is easier, because the elements under investigation are more exposed, improving the visual examination. However, the bones become more fragile under carbonization, which can cause structural loss. Furthermore, much information is lost when the bones are not found, impairing the dental identification.



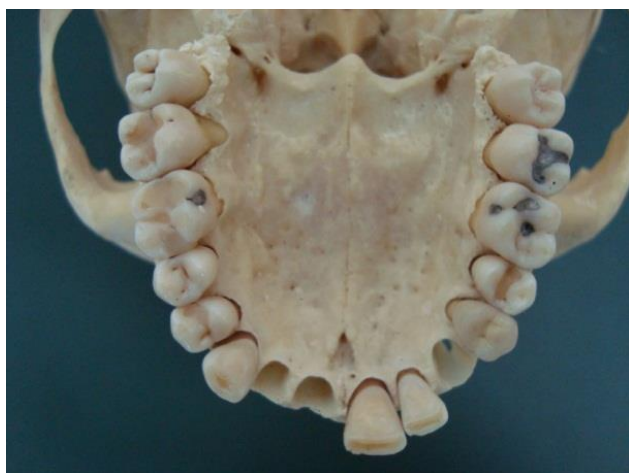

Figure 4. Maxilla with dental elements helping to identify the body.

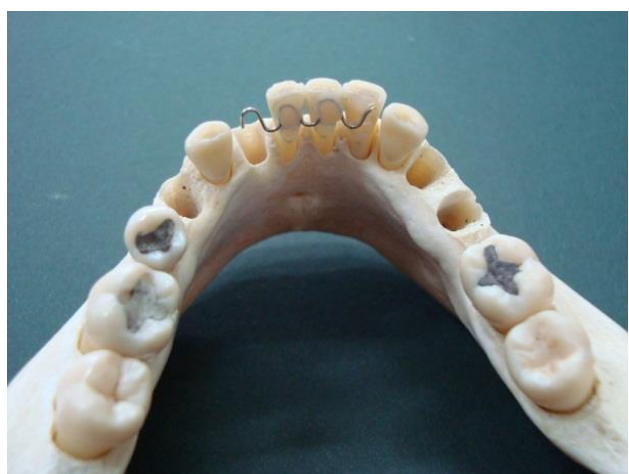

Figure 5. Jaw with contention in anterior teeth showing orthodontic treatment.

The dental identification has some limitations. Having good quality dental radiographies for comparison is not a common practice among dentists, who sometimes do not store the radiographies properly and even lose them. Photographs, study models, and clinical records also are used in this process. Another limitation can come from serious trauma like beheading, which makes the dental identification impossible if the head is not found. Moreover, forensic dental examinations are not done only on unidentified corpses, but also on drowned, polytraumatized and carbonization (Figure 6). Even if the person has already been identified, an examination is done in order to confirm the identification, mainly in cases where the corpse is in an advanced state of putrefaction.

Another great challenge is the positive identification of incinerated human remains, showing the importance of a multi-disciplinary approach to the identification of such remains. Forensic odontologists and anthropologists need to be included in the body recovery process in order to maximize the recovery of evidence and to ensure that all possible ways for positive identification were explored.

This helps to avoid the need of a robust method of circumstantial identification [20].



Figure 6. Arrival of the carbonized victim at the Legal Medical Station.

Dentists can also use the DNA exam to identify a corpse. Although it is onerous to the State, it is a commonly used method in cases when there are a few elements on the corpse like teeth or large bones and a family's blood for comparison.

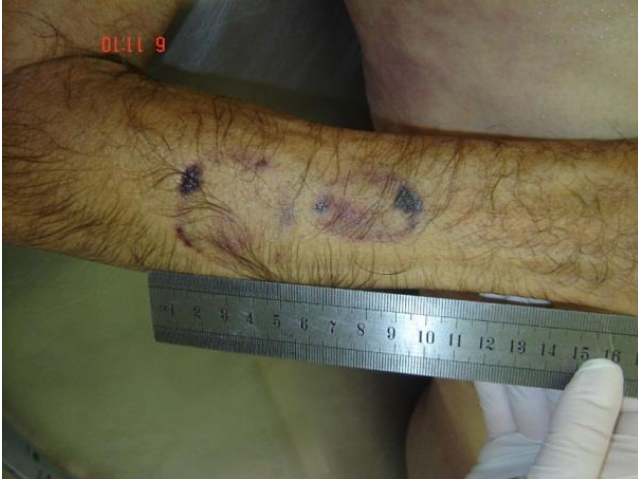There is a wide range of laboratory tests for human identification and biological materials as a source of DNA such as bone tissue, capillary bulb, biopsy's material, saliva, blood, dentin, dental pulp, etc. It is possible to get DNA from almost any tissue of the human body, the only difference being the amount of DNA that is possible to extract from each of these tissues [19].

Forensic Dentistry is an established science for human identification, mainly in cases when there are few remains to do so (fires, explosions, decomposed or skeletonized bodies). This has forced the dentists who deal with forensic investigations to be familiar with new technologies of molecular biology. The main objective of the forensic analysis of DNA is to get a precise identification of a subject with almost zero probability of mistakes. This makes it necessary to involve multi professional staffs with knowledge and experiences in a variety of specialties [13, 20-21].

Evaluating the best method of DNA extraction depends on the available sample. The forensic dentist must be careful while collecting and delivering the material, because all of these samples are used for several types of exams and are sent to the toxicology, pathology, DNA, chemistry, anthropology, and forensic laboratories in Porto Alegre, the capital city of Rio Grande do Sul State, Brazil. Apart from the proceedings for DNA extraction of teeth, the forensic dentist must present a report, describing in detail what he observed in the exam, including the methodologies employed and the results obtained. All the different exams need to be interpreted

and complement each other with the aim to have a successful investigation.

Another way of obtaining DNA material is through the saliva. The saliva can be collected from living people, corpses (in cases of bite marks) (Figure 7), and clothes. It can also be collected from objects found at the crime scene, for example, cigarettes, stamps, glasses. It is also identified by the Woods lamp (filtered ultraviolet light) [4].



**Figure 7.** Bite marks to the human identification.

Even when there is no suspect, the collection must be done, because it is a perishable item and it can be easily destroyed or removed by the manipulation of evidence. According to Sweet [20], the DNA concentration in saliva remains stable on the corpse up to 24h and up to 48h on the skin. Thus, it is important to avoid the contamination of the saliva sample. The process of collecting a saliva sample is [22]: 1) wet swab with sterilized or distilled water or saline solution; 2) roll the swab along the skin surface, in the bitten area, and around it; 3) let it dry at room temperature; 4) roll a second dry swab over the area to absorb all moisture left by the first swab; 5) let this swab dry at room temperature and 6) pack both swabs together and send them to the DNA Laboratory. If necessary, store the sample in a refrigerator.

This method of collecting DNA samples from saliva is used in cases of violence involving indecent assault or body lesions, mainly when the bite is present in the victim or in the aggressor.

### 3. DISCUSSION

This paper presented the state of things in Brazil in terms of legal framework and the availability of personnel with a view to presenting an overview of proper daily work in forensic Institute in Pelotas city. Forensic odontology is the forensic science that is concerned with dental evidence. It is a relatively new science that utilizes the dentist's knowledge to serve the judicial system.

Human identification relies heavily on the quality of dental records and plays a key role in natural and man-made disaster particularly aviation disaster. Dental structures are the hardest and most resilient tissues of the human body [23]. Forensic dentistry is a branch of forensic medicine, which in the interest of justice, deals with the proper handling in examination of dental evidence with the proper evaluation and presentation of dental findings [24].

However, working in Legal Medical Institutes means to be involved in a team work with several departments connected. Hence, all tasks must be executed in harmony and cooperation between the expert professionals, with the aim to guarantee the optimization of the final work that is to solve the criminal investigation.

The scientific literature contains very little about the role of the expertise's routine in the specific areas of forensic investigations and collection of evidence. In the last four decades, dental evidence like teeth, palatal rugae patterns, dental anomalies, has been recognized as the most reliable method for identification of victims during the investigation of mass disasters [25-26]. Teeth are often submitted to forensic laboratories as the only piece of physical evidence due their high resistance to fire and postmortem changes [27], as well as these remains are useful representative for the identification of corpses after long periods of burial [28]. The recovery of dental tissues permits the use to evaluate teeth, periodontal tissue and anatomical features and use them to DNA test [29] Teeth on exposure to post-mortem influences will survive longer than other body tissues as the materials used to restore damaged teeth are extremely resistant to physical, chemical, and biological destruction [23].

Dental identification assumes a primary role in the identification of remains when post-mortem changes, traumatic tissue injury or lack of a fingerprint record invalidate the use of visual or fingerprint methods. The identification of dental remains is of primary importance when the deceased person is skeletonized, decomposed, burned or dismembered [30].

The identification through forensic science deals with the proper handling and examination of dental evidence and proper evaluation and presentation of dental findings in interest of justice.

Forensic identification based on assessment of prosthodontic appliances is assuming greater significance, as labelling of dentures and other prosthetic appliances could provide vital clues for patient identification [24]. Denture marking or labeling is not a new concept in either Prosthetic or Forensic dentistry and its routine practice has been urged by Forensic dentists internationally for many years. Denture marking is accepted as a means of identifying dentures and persons in geriatric institutions or post mortem during war, crimes, and civil unrest, natural and mass disasters. Prosthodontists are playing

very important role in forensic dentistry, as they are concerned with fabrication of various prostheses, which can serve as an important tool for identification. Identification is essential requirement of any medico-legal investigation because a wrong identity may pose a problem in delivering justice. There are various methods of denture marking and is important for person identification in legal medical investigations [31].

There is low knowledge about the applications of forensic odontology in routine practice; hence, steps must be taken to educate the dental practitioners about its clinical applications [32].

Rothwell [17] assumed that Forensic Dentistry methods play a key role in the identification of decomposed corpse remains. It is essential to know the routine and the context where it is inserted to the institution's growth and help the development of new technologies and methods.

Unfortunately, the processes of Forensic Dentistry, mainly regarding necropsies and corpses' identification, in the State of Rio Grande do Sul is not often used. This is due to the difficulty of having good radiographs and clinical reports from the dentists of the victims and because sometimes the dental work was not finished. Generally, the DNA test is done when people are looking for their relatives. The age determination of a child who suffered any aggression is done through the teeth radiographies and the stages of tooth mineralization.

Furthermore, planning is crucial for successful identification of victims and a special identification team should be responsible for the work. Any pre-planning of disaster victim identification process since dental evidence is a powerful tool in the identification of dead.

It is the need of us to establish a consensus in some forensic procedures performed, during the post-mortem evidence collection, preservation and analysis of dental evidence and in the most suitable identification technique based on the disaster situation [33].

#### 4. CONCLUSION

We concluded that the structure of the Legal Medical Station in a southern Brazilian city, as Pelotas, presents full conditions for the Forensic Dentistry practice, allowing an interdisciplinary work in the search of crime solution. Hence, it is essential to stimulate and call attention to the study of this area in developing countries like Brazil, where the number of specialists is increasing.

#### REFERENCES

- [1] I.A. Pretty. Forensic dentistry: 1. Identification of human remains. *Dent Update*, **34(10)**, 621-2, 624-6, 629-30, 2007.
- [2] Brazilian Federal Council of Dentistry. Consolidation of standards for procedures in the councils of Dentistry: approved by Resolution CFO nº 63/ 20058. Accessed 2/Dec/2014 at: <http://cfo.org.br/wp-content/uploads/2009/10/consolidacao.pdf>  
<http://www.cfo.org.br/index.htm>
- [3] M.S. Patil; S.B. Patil; A.B. Acharya. Palatine rugae and their significance in clinical dentistry: a review of the literature. *J Am Dent Assoc*, **139(11)**, 1471-8, 2008.
- [4] B.R. Chandra Shekar; C.V. Reddy. Role of dentist in person identification. *Indian J Dental Res*, **20(3)**, 356-60, 2009.
- [5] G. Li. The role dental profession can play in mass casualty and disaster events. *Hua Xi Kou Qiang Yi Xue Za Zhi*, **26(4)**, 347-51, 2008.
- [6] S.C. Sarode; G.A. Zarka; M.A. Kulkarni; R. Desai. Role of forensic odontology in the world's major mass disasters: facts and figures. *South African Dental Journal*, **64(9)**, 388-390, 392-393, 2009.
- [7] A. Valenzuela; S. Martin-de las Heras; T. Marques; N. Exposito; J.M. Bohoyo. The application of dental methods of identification to human burn victims in a mass disaster. *Int J Legal Med*, **113(4)**, 236-9, 2000.
- [8] P. Nambiar; N. Jalil; B. Singh. The dental identification of victims of an aircraft accident in Malaysia. *Int Dent J*, **47(1)**, 9-15, 1997.
- [9] J. Dumancic; Z. Kaic; V. Njemirovski; H. Brkic; D. Zecevic. Dental identification after two mass disasters in Croatia. *Croat Med J*, **42(6)**, 657-62, 2001.
- [10] R.B. Brannon; W.M. Morlang. The USS Iowa disaster: success of the forensic dental Team. *J Forensic Sci*, **49(5)**, 1067-8, 2004.
- [11] Wikipedia web site. Gol transportes aéreos Flight 1907. February 1, 2015. Accessed 20/2/2015 at: [http://en.wikipedia.org/wiki/Gol\\_Transportes\\_A%C3%A9reos\\_Flight\\_1907](http://en.wikipedia.org/wiki/Gol_Transportes_A%C3%A9reos_Flight_1907).
- [12] BBC News on line. Brazil trial over plane crash that killed 199 August 8, 2013. Accessed 20/2/2015 at: <http://www.bbc.com/news/world-latin-america-23609524>.
- [13] D. Sweet. Why a dentist for identification? *Dent Clin North Am*, **45(2)**, 237-51, 2001.
- [14] Brazilian Institute of Geography and Statistics (IBGE). Sample results of the 2010 Population Census - Lattice digital city in Brazil: Situation in 2010. November 29, 2010. Accessed 20/02/2015 at: <http://www.censo2010.ibge.gov.br/sinopse/index.php?uf=43&dados=8>.
- [15] L.D. Conceição; R.G. Lund; G.G. Nascimento; R.H.A. Silva; F.R.M. Leite. Non-white people have a greater risk for maxillofacial trauma: findings from a 24-month retrospective study in Brazil. *Braz J Oral Sci*, **12(4)**, 313-318, 2013.
- [16] BRASIL. Decreto-Lei Nº 3.689, 3 de outubro de 1941. [Rules on the Body Delict Exam and expertnesses in general]. In: CASA CIVIL. Código de Processo Penal. Rio de Janeiro, 1941. October 13, 1941. Accessed 08/02/2015 at: [http://www.planalto.gov.br/ccivil\\_03/Decreto-Lei/Del3689.htm](http://www.planalto.gov.br/ccivil_03/Decreto-Lei/Del3689.htm)
- [17] B.R. Rothwell. Principles of dental identification. *Dent Clin North Am*, **45(2)**, 253-70, 2001.
- [18] F.S. Benfica; M. Vaz; M. Rovinski; M.S.T. Costa. In: Rio Grande do Sul Legal Medical Department Routines

- Book. Benfica FS, Vaz M, Rovinski M, Costa MST (Editors). Porto Alegre: Legal Medical Station, p. 10-19, 2004.
- [19] N. Rudin; K Inman. An introduction to forensic DNA analysis. Florida: CRC Press, 2002.
- [20] M. Skinner; D. Alempijevic; A. Stanojevic A. In the absence of dental records, do we need forensic odontologists at mass grave sites? *Forensic Sci Int*, **201(1-3)**, 22-26, 2010.
- [21] R.H.A. Silva; J.O. Musse; R.F.H. Melani; R.N. Oliveira. Human bite mark identification and DNA technology in forensic dentistry. *Braz J Oral Sci*, **5**, 1193-7, 2006.
- [22] D. Sweet; M. Lorente; J.A. Lorente; A. Valenzuela; E. Villanueva. An improved method to recover saliva from human skin: the double swab technique. *J Forensic Sci*, **42(2)**, 320-2, 1997.
- [23] R. Kapoor; R. Singh; K. Singh; K. Kaur. "Denture Marking" A Novel Concept in Human Identification. *IOSR Journal of Dental and Medical Sciences*, **14(3)**, 67-70, 2015.
- [24] S.K. Mishra; H. Mahajan; R. Sakorikar; A. Jain. Role of prosthodontist in forensic odontology. A literature review. *J Forensic Dent Sci*, **6(3)**, 154-59, 2014.
- [25] D.H. Clark. An analysis of the value of forensic odontology in ten mass disasters. *Int Dent J*, **44(3)**, 241-50, 1994.
- [26] J.O. Obafunwa; F.A. Faduyile; S.S. Soyemi; U.O. Eze; E.J. Nwana; W.O. Odesanmi. Forensic Investigation of mass disasters in Nigeria: A review. *Niger Med J*, **56(1)**, 1-5, 2015.
- [27] S. Fischman. The use of medical and dental radiographs in identification. *Int Dent J*, **35(4)**, 301-6, 1985.
- [28] R. Wood; C. Tai; B. Blenkinsop; D. Johnston. Digitized slice interposition in forensic dental radiographic identification. *Am J Forensic Med Pathol*, **15(1)**, 70-8, 1994.
- [29] I.A. Pretty; D. Sweet. A look of forensic dentistry – Part I: The role of teeth in determination of human identity. *Br Dent J*, **190(7)**, 359-66, 2001.
- [30] R. Goswami; R. Garg; R. Jolly. Role of prosthodontics in Forensic Odontology. *International Journal of Clinical Dental Science*, **2(4)**, 85-9, 2011.
- [31] J. Mohan; C.D. Kumar; P. Simon. "Denture marking" as an aid to forensic identification. *J Indian Prosthodont Soc*, **12(3)**, 131-6, 2012.
- [32] P. Khare; S. Chandra; V. Raj; P. Verma; G. Subha; A. Khare. Status of forensic odontology in metro and in tier 2 city in urban India. *J Forensic Dent Sci*, **5(2)**, 134-7, 2013.
- [33] P.M. Puri; H. Khajuria. Disaster Victim Identification (DVI) through Dental Evidence: Overview and Challenges in Indian Scenario. *International Journal of Research and Scientific Innovation*, **2(2)**, 54-57, 2015.